

Refereed

TREATMENT OF TENDON INJURIES IN THOROUGHBRED RACEHORSES USING CARBON-FIBER IMPLANTS

K.P. Reed, DVM;¹ S.S. van den Berg, DVM;² A. Rudolph, DVM;³
James A. Albright, MD;⁴ Harold W. Casey, DVM, MPH, PhD;⁵ A.A. Marino, PhD⁶

SUMMARY

In two separate studies, implanted carbon fibers were used to treat tendinitis of the digital flexor tendon in Thoroughbred racehorses. In the first study, in 28 horses that were salvage cases, 57% ($P < 0.05$) healed sufficiently to be able to return to competitive racing after receiving carbon fibers. In the second study, 19 horses received carbon fibers within 30 days of injury, and 74% returned to racing compared with 23% of the 26 horses in a historical control group ($P < 0.05$). The results indicated that use of carbon fibers was an effective treatment for equine digital flexor tendinitis in both chronic and subacute injuries. Histological studies showed that the carbon fibers were biocompatible and suggested that the mechanism of their action involved induction of fibrous tissue or increased vascularization.

INTRODUCTION

Digital flexor tendinitis is a particularly debilitating injury in the athletic horse because the large physical forces

transmitted by the tendons during racing and the possible loss of tendon elasticity frequently result in re-injury. Various attempts have been made to augment normal healing, including thermocautery, tendon-splitting, autologous-tissue grafting, check ligament desmotomy, and synthetic prostheses, but none of these procedures has been shown in a controlled study to be superior to conservative therapy.

Implanted carbon fibers have been studied in both strained and transected tendons in horses. In the latter cases, the carbon fibers were woven through the tendon and secured using sutures and knots, with generally poor results.^{1,2,3,4} The results were more promising when the carbon fibers were implanted without fixation in strained, but intact, tendons.^{5,6,7} In 40 horses in which a bundle of 40,000 carbon fibers was implanted in a surgically-created T-shaped bed in the tendon, 6 returned to racing, 3 failed, and 31 were in training.⁵ In 7 horses (5 salvage cases) in which bundles of 5,000 carbon fibers were passed through the tendon using a cannula, 3 returned to previous use, and 4 were in training.⁶ In 34 horses in which bundles of 40,000 carbon fibers were introduced percutaneously using a curved needle, the success rate was 21%.⁷

Based on the studies involving strained tendons and on our studies of the tissue reaction to carbon fibers of known purity and composition in animals and humans,^{8,9,10,11,12,13} it appeared that carbon fibers might be useful for treating tendinitis of the digital flexor tendons in racehorses. The results of two clinical studies designed to test this hypothesis are reported here. In addition, histological studies were performed in a separate group of horses to examine the biocompatibility of carbon fibers and their ability to induce connective-tissue growth and

Authors' addresses: ¹Equine Medicine and Surgery, Benton, Louisiana USA. ²Department of Surgery, Faculty of Veterinary Science, University of Pretoria, Onderstepoort, Republic of South Africa. ³Johannesburg, Republic of South Africa. ⁴Department of Orthopaedic Surgery, Louisiana State University Medical Center, Shreveport, Louisiana. ⁵Department of Veterinary Pathology, School of Veterinary Medicine, Louisiana State University, Baton Rouge, Louisiana. ⁶Department of Orthopaedic Surgery, Department of Cellular Biology and Anatomy, Louisiana State University Medical Center, P.O. Box 33932, Shreveport, Louisiana. 71130-3932; 318-674-6180. Fax: 318-674-6186.

increased vascularization. Preliminary results of the clinical study were reported previously.¹⁴

METHODS

Two separate studies were conducted. In the first, 28 injured Thoroughbred racehorses that failed treatment for tendinitis consisting of rest and drugs, and were therefore unable to return to competitive racing, received carbon fibers in the injured tendons. The average elapsed time between injury and the implant surgery was 11 months. In each instance, entry into the study was the alternative to retirement from competitive racing, and the horse was not accepted into the study unless the owner agreed to carry out the proposed plan for rehabilitation to the point where the horse either returned or failed to return to the racetrack. Horses with unilateral or bilateral injuries to the superficial digital flexor tendon (SDFT) or deep digital flexor tendon (DDFT) were included. Because there is no objective and quantifiable classification system for equine tendinitis, a standardized system was devised and implemented in which the degree of injury in each limb was classified as slight (+), moderate (++) or severe (+++), taking into consideration the extent of the lesion, pain, swelling, degree of lameness, amount of fibrosis and hard swelling, and soundness when walking and trotting. Generally, a slight injury corresponded to fiber disruption estimated to be less than 20% of the tendon cross-section when viewed with ultrasound; moderate and severe corresponded to injuries of 20-40% and >40%, respectively. However, it was the overall result of the clinical examination, and not any particular symptom or measurement that determined the assigned class. If the tendon lesion extended to within 2 cm of the annular ligament, the horse was excluded from study; 3 horses were excluded on this basis. Since each horse had already failed a previous treatment, it was treated for statistical purposes as its own control.

In the second study, 19 horses received carbon fibers within 30 days of injury; the study was restricted to unilateral injuries involving only one tendon. A randomized control group was not included because the successful return of a racehorse to the racetrack following injuries of the severity studied was felt by the individual owners to be unlikely, and they refused to participate in the study if not randomized to the carbon-fiber group. Consequently, a control group for the second study was chosen from horses that had been treated for tendinitis and that met the other entry criteria; the controls were contributed by one veterinary practice because of the availability of the medical records necessary to insure the choice of appropriate controls. Four control horses were treated concurrently with the carbon-fiber horses (because the owner refused carbon-fiber treatment), and 22 were obtained from the medical records from the immediately preceding five-year pe-

riod. A consecutive series was formed consisting of Thoroughbred racehorses with injuries comparable in severity to the horses that received carbon fibers. The historical and concurrently-treated controls were slowly prepared for racing similarly to the horses that received carbon fibers. The distribution of horses among the injury grades did not differ between the carbon-fiber and control groups, as determined using the χ^2 test.

The implant (CFS[®], Plastafil, Horizon, RSA) was approximately 1.5 mm in diameter and 20 cm long, and consisted of 4 carbon-fiber bundles of 10,000 fibers each, lashed together at the ends using synthetic absorbable suture material. Each carbon fiber was about 8 μ m in diameter and was composed of 92% carbon, 7% nitrogen, and trace amounts of oxygen. Neither epoxy nor any other potentially tissue-toxic substance was used during manufacture of the fibers. Adhering broken fibers and debris produced during the manufacturing process were removed from the implant in an ultrasonic bath, and the implant was coated with gelatin/glycerol to facilitate handling during surgery. The surgical instruments used for placing the implant in the tendon are shown in Figure 1. The version of the CFS[®] that was available at the time of this study could not reliably be detected by ultrasound.

The surgical procedure, a modification of Littlewood's method,⁶ was performed under general anesthesia with the horse in lateral recumbency. The area between the carpus and the pastern joint was shaved, and the limb was fixed in extension to obtain the correct angle for the introduction of the instruments. After preparing a sterile field, a stab wound was made through the skin to the center of the SDFT at about 10 cm distal to the tendon lesion; where necessary, the wound penetrated the SDFT to the center of the DDFT. A trocar and cannula were inserted through the incision up the center of the tendon to near the carpometacarpal joint; when the trocar was removed, the implant could be placed into the tendon through the cannula. The cannula was then removed, and the tendon sheath and skin were sutured. The entire procedure was completed in 5-10 minutes. A support bandage was applied immediately after surgery and changed every 3-4 days as needed.

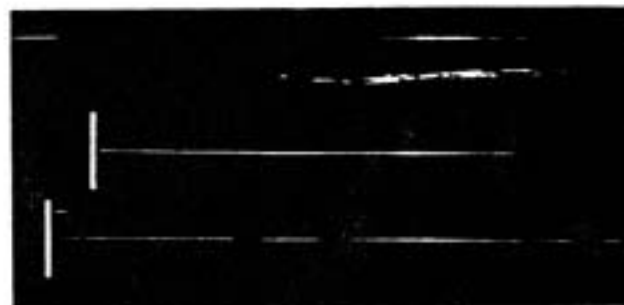


Figure 1. Surgical instruments for inserting carbon fibers in the digital flexor tendons (Plastafil, Horizon, RSA). From left to right: probe, cannula, implant (about 20 cm long), introducer.

Table 1. Use of carbon fibers in racehorses that failed initial conservative treatment for tendinitis of the digital flexor tendons consisting of rest and drugs. SDFT, superficial digital flexor tendon. DDFT, deep digital flexor tendon. LF, RF, left and right forelimb, respectively. ↓, ↑, treatment failure and success, respectively. The number of races successfully completed at the time of the last follow-up is shown in parentheses. Degree of injury: +, slight; ++, moderate; +++, severe. Statistical significance was determined using McNemar's test for repeated measures.⁸

HORSE	AGE (years)	LIMB	INJURED TENDON	DEGREE OF INJURY	PRIOR TREATMENT		CARBON FIBERS
					Months	Result	
1	5	RF	SDFT	++	4	↓	↑ (17)
2	4	LF	SDFT	++	5	↓	↑ (1)
3	4	LF	SDFT	++	6	↓	↑ (2)
4	5	LF	SDFT	++	6	↓	↓
5	3	RF	SDFT	++	6	↓	↑ (5)
6	4	LF	SDFT	+++	6	↓	↑ (4)
7	5	LF	SDFT	++	6	↓	↓
8	3	LF	SDFT	++	7	↓	↓
9	6	LF	SDFT	++	7	↓	↓
10	3	RF	SDFT	+++	9	↓	↓
11	3	RF	SDFT	+++	9	↓	↑ (1)
12	3	RF	SDFT	++	9	↓	↓
13	4	LF	SDFT	++	9	↓	↑ (8)
14	6	RF	SDFT	++	12	↓	↑ (3)
15	6	LF	DOFT	+++	14	↓	↑ (32)
16	5	LF	SDFT	+++	19	↓	↑ (19)
17	4	LF	SDFT	+++	24	↓	↑ (7)
18	3	RF	SDFT	++	6	↓	↑ (2)
		RF	DOFT				
19	4	RF	SDFT	+++	11	↓	↓
		RF	DOFT				
20	5	LF	SDFT	+++	18	↓	↑ (2)
		LF	DOFT				
21	3	RF	SDFT	+++	24	↓	↑ (5)
		RF	DOFT				
22	4	RF	SDFT	+++	13	↓	↓
		LF	DOFT	+			
23	2	LF	SDFT	+	4	↓	↑ (4)
		RF	SDFT	+			
24	4	LF	SDFT	+++	6	↓	↑ (6)
		RF	SDFT	++			
25	5	LF	SDFT	+++	19	↓	↓
		RF	SDFT	++			
26	3	LF	SDFT	++	20	↓	↓
		RF	SDFT	++			
27	4	LF	SDFT	+++	6	↓	↓
		RF	SDFT	+++			
		LF	DOFT				
28	6	LF	SDFT	+++	24	↓	↓
		RF	SDFT	++			
		LF	DOFT				

Overall fractional success 0/28*

16/28*
*P < 0.05




Figure 2. Representative longitudinal sections showing tissue induced inside carbon-fiber bundles implanted in the equine superficial digital flexor tendon; A, 6 months; B, 14 months. The individual carbon fibers (8 μ m in diameter) were shattered by the diamond knife, and some of the debris was displaced from its original bed.

and stained with Toluidine O/basic fuchsin. The method permits study of the induced tissue that occurred at known distances from the carbon surface (because the actual carbon-fiber bed can be directly observed).

The effect of carbon fibers in the first study was evaluated by McNemar's test for repeated measures.¹⁸ The data from the second study was evaluated using the χ^2 test. The chosen significance level was $P < 0.05$ in both cases.

RESULTS

Study No. 1

The results are shown in Table 1. Horses 1-17 each suffered a moderate or severe injury to one tendon (the SDFT in all but one case), were treated with rest and drugs for the indicated periods, but were unable to return to competitive racing. Following implantation of carbon fibers and the subsequent period of rehabilitation, 65% (11/17) horses successfully completed one or more races. Horses 18-28 (Table 1) had sustained multiple tendon injuries. After receiving carbon fibers in each of the injured tendons, 45% (5/11) of the horses returned to racing. Thus, the overall success with carbon fibers in the salvage group was 57% (16/28) ($P < 0.05$).

Study No. 2

Carbon fibers were implanted within 30 days of an injury to one tendon (the SDFT in all but one case), with the result that 74% of the horses (14/19) returned to racing (Table 2). The success rate in the control group, which was comparable to the carbon-fiber group with regard to age, degree of injury, and extent of rehabilitation, was 23% ($P < 0.05$).

Histological Studies

In 5 horses implanted with carbon fibers in the SDFT and sacrificed 6-25 months thereafter, similar histologic

features were seen in all cases. Tissue ingrowth occurred between individual carbon fibers and formed a matrix of collagen fibers, fibroblasts/fibrocytic cells, and thin-walled blood vessels; the amount of tissue ingrowth increased between 6-14 months postoperatively (Figure 2), but not thereafter. Macrophages were occasionally seen in perivascular locations, but eosinophils, foreign-body giant cells, and phagocytosis of carbon-fiber particles were not observed.

DISCUSSION

Several factors must be considered in evaluating the usefulness of carbon fibers in the treatment of tendinitis in racehorses. In the first study (Table 1), each horse served as its own control because each had failed a previous treatment that consisted principally in an extended period of rest. A second similar treatment might have resulted in the successful return of some of the horses to the racetrack; consequently, the results (Table 1) tend to overestimate the efficacy of carbon fibers because they counted as successes both (1) horses that benefited from the implants and (2) horses that benefited solely from the concomitant rest period. Moreover, it is possible that some of the horses would have been successes if they had received a different initial treatment; for example, Bramlage reported that 79% of horses that received radial check ligament desmotomy returned to racing.¹⁷ However, the success rate for initial treatment of tendinitis of the digital flexor tendons in racehorses is generally low (about 23% in our study, Table 2, Control cases), and the success rate for a group of horses that received a second control treatment would probably be still lower. It is, therefore, unlikely that an appreciable percentage of the horses would have returned to racing if they had been treated a second time with rest and drugs, but without carbon fibers.

In the second study (Table 2), the control cases were

drawn from only one of the 3 veterinary practices that contributed the carbon-fiber cases (because of the availability of necessary historical documentation); this raises the issue of the comparability of the two groups. The control and carbon-fiber cases were similar with respect to age, degree of injury, and extent of post-injury rehabilitation. In addition, an analysis of the success/failure ratios using carbon fibers in each of the 3 practices disclosed no significant differences among the practices, suggesting that it is unlikely that there would have been significant differences between practices involving conservatively managed horses. These considerations indicated that the control group was a reasonable basis for comparison.

Either the implant itself or the tunnel created by the cannula could sometimes be resolved in the longitudinal plane immediately using ultrasound. Thereafter, as tissue grew into the fiber bundle, the implant became anechoic. Thus, ultrasound was generally not useful for documentation of the position of the implant in relation to the lesion. Although the goal of the surgical procedure was to traverse the lesion with the implant, it was possible that some lesions were peripheral to the implant or extended more distally than the implant (the implant entered the tendon a minimum of 2 cm below the estimated distal margin of the lesion). Both factors biased against carbon fibers because any clinical failure would have been attributed to the lack of efficacy of the implant rather than to its mispositioning. Thus, the absence of documentation of position tended to produce error in the direction of concluding that carbon fibers were not efficacious (type 2 statistical error).

The scale for assessment of injury may have resulted in classification of some horses that would not have been uniform among all equine practitioners. Nevertheless, since it was applied consistently throughout both studies, disagreement concerning the classification of individual horses would not be expected to have a material impact on the evaluation of the usefulness of carbon fibers.

Some horses had never raced prior to injury, and consequently, had not established a level of performance; in other cases, follow-up ended before individual horses' ultimate performance levels were established. Consequently, it was not possible to directly assess level of performance in relation to treatment with carbon fibers.

Despite the uncertainties, it is reasonable to conclude that the observed success rate in the horses that received the implant was greater than would otherwise have occurred, and was due to the carbon fibers and not simply to the concomitant rehabilitation procedures followed in the study. But since sham surgical procedures were not performed (insertion of the cannula but no implant), the quantum of the effect attributable to the surgical procedure, if any, is unknown. In the future, use of a severity rating scale such as that developed by Genovese et al.¹⁸ for quantitating lesions of the SDFT using ultrasound might permit more effective use of carbon fibers, particularly if the implant

can be modified to increase its echogenicity.

The enhanced ability of the horses that received carbon fibers to return to competitive racing could not have been derived from the mechanical strength of the carbon fibers because the implant was not sutured or otherwise affixed to the host tendon. Previous studies involving use of carbon fibers in the gastrocnemius tendons in rabbits,^{9,12} cranial cruciate ligament in goats,¹⁰ abdominal-wall muscles in rats¹³ and anterior cruciate ligaments in humans⁸ showed that the biological response to the type of carbon fibers used here was growth of a connective-tissue matrix that was well supplied with blood vessels, and the tissue response in horses was similar (Figure 2). Although most studies of tissue response to carbon fibers have similarly reported excellent biocompatibility,^{21,22,23,24,25,26} adverse histological changes have also been reported.^{27,28} There have been no reports of adverse tissue changes involving the animal or human use of carbon fibers having the purity of those used in this study.

The mechanism of action of the carbon fibers could have involved the induced connective tissue that occurred as a result of the implant. The induced tissue, which was longitudinally oriented and traversed the region of the lesion, may have functioned as an internal stent thereby adding mechanical strength at the site of the defect. Alternatively, the mechanism of action might have involved the increased vascularization that occurred in response to the carbon fibers. The blood supply of the equine superficial digital flexor tendon is primarily intratendinous, and its middle third is least well vascularized.²⁹ The increased vascularization induced by the implant may have favorably altered the amount or quality of the repair tissue at the site of the lesion.

REFERENCES

1. Bertone AL, Stashak TS, Smith FW, Norrdin RW: A comparison of repair methods for gap healing in equine flexor tendon. *Vet Surg* 19:254-265, 1990.
2. Brown MP, Pool RR: Experimental and clinical investigations of the use of carbon fiber sutures in equine tendon repair. *J Am Vet Med Assoc* 182:956-966, 1983.
3. Nixon AJ, Stashak TS, Smith FW, Norrdin RW: Comparison of carbon fibre and nylon suture for repair of transected flexor tendons in the horse. *Eq Vet J* 16:93-102, 1984.
4. Valdez H, Clark RG, Hanseika DV: Repair of digital flexor tendon lacerations in the horse, using carbon fiber implants. *J Am Vet Med Assoc* 177:427-435, 1980.
5. Goodship AE, Brown PN, Yeats PN, Jenkins DHR, Silver IA: An assessment of filamentous carbon fibre for the treatment of tendon injury in horse. *Vet Rec* 106:217-221, 1980.
6. Littlewood HF: Treatment of sprained tendons in horses with carbon fibre implants. *Vet Rec* 105:223-224, 1979.
7. Vaughan LC, Edwards GB, Gerring EL: Tendon injuries in horses treated with carbon fibre implants. *Eq Vet J* 17:45-50, 1985.
8. Demmer P, Fowler M, Marino AA: Use of carbon fibers in the reconstruction of knee ligaments. *Clin Orthop* 271:225, 1991.

9. Keating AM, Marino AA, Albright JA, Specian RO: Functional repair of rabbit gastrocnemius tendons using carbon fibers. *Clin Orthop* 209:292-297, 1986.
10. Keating AM, Marino AA, Albright JA: Tissue induction by carbon fibers in goat cruciate ligaments. Submitted, 1994.
11. Marino AA, Fronczak A, Boudreaux C, Lyles DN, Keating EM, Albright JA: Orthopaedic applications of carbon fibers. *IEEE Trans Eng Med Biol* 5:31-34, 1986.
12. Marino AA, Albright JA: Long-term effects of carbon fibers in rabbit Achilles tendons. Submitted, 1994.
13. Morris DM, Marino AA, Haskins R, Misra R, Rogers S, Fronczak S, Albright JA: Carbon fibers for repair of abdominal-wall defects in rats. *Surgery* 107:627-631, 1990.
14. Van Den Berg SS, Reed KP, Marino AA: Use of carbon fibers for the repair of bowed tendons: a preliminary report. *J Eq Vet Sci* 8:339-340, 1988.
15. Stashak TS: *Adams' Lameness in Horses*, 4th Ed. Lea & Febiger, Philadelphia, 1987.
16. Dixon WJ, Massey FS: *Introduction To Statistical Analysis*, 4th Ed. McGraw-Hill, New York, 1983.
17. Bramlage LR: Superior check desmotomy as a treatment for superficial digital flexor tendinitis: Initial report. *Proc 32nd Ann Conv Am Assoc Equine Pract*. 32:365-369, 1986.
18. Genovese RL, Rantanen NW, Simpson BS, Simpson DM: Clinical experience with quantitative analysis of superficial digital flexor tendon injuries in Thoroughbred and Standardbred racehorses. *Vet Clin N Am* 6:129-145, 1990.
19. Amis AA, Kempson SA, Campbell JR, Miller JH: Anterior cruciate ligament replacement; biocompatibility and biomechanics of polyester and carbon fiber in rabbits. *J Bone Joint Surg* 70B:628-634, 1988.
20. Jenkins DHR: Ligament induction by filamentous carbon fiber. *Clin Orthop* 196:86-87, 1985.
21. Jenkins DHR, Forster IW, Mckibbin B, Ralis ZA: Induction of tendon and ligament formation by carbon implants. *J Bone Joint Surg* 59B:53-57, 1977.
22. Kramer B: Histological appearance of carbon-fiber implants and neoligament in man. *S Afr Med J* 63:113-115, 1983.
23. Lemaire M: The use of carbon fibers in surgery. In *Alloplastic Ligament Replacement*. C. Buri and L. Claes, Eds. Hans Huber, Vienna, 1985.
24. Parsons JR, Bhayani S, Alexander H, Weiss AB: Carbon fiber debris within the synovial joint: a time-dependent mechanical and histologic study. *Clin Orthop* 196:69-76, 1985.
25. Rushton N, Rae T: The intra-articular response to particulate carbon fiber reinforced high-density polyethylene and its constituents: an experimental study in mice. *Biomaterials* 5:352-356, 1984.
26. Weiss AB, Blazina ME, Goldstein AR, Alexander H: Ligament replacement with an absorbable copolymer carbon fiber scaffold: early clinical experience. *Clin Orthop* 196:77-85, 1985.
27. Bray RC, Flanagan JP, Dandy DJ: Reconstruction for chronic anterior cruciate instability. *J Bone Joint Surg* 70B:100-105, 1988.
28. Dandy DJ, Flanagan JP, Steenmeyer V: Arthroscopy in the management of ruptured anterior cruciate ligament. *Clin Orthop* 167:43-49, 1982.
29. Kraus-Hansen AE, Fackelman GE, Becker C, Williams RM, Pipers FS: Preliminary studies on the vascular anatomy of the equine superficial digital flexor tendon. *Eq Vet J* 24:46-51, 1992.