

## Lung Damage in Mice Following Intraperitoneal Injection of Butylated Hydroxytoluene<sup>1</sup> (36407)

ANDREW A. MARINO AND JOHN T. MITCHELL  
(Introduced by Robert M. Dougherty)

*Veterans Administration Hospital and Upstate Medical Center, Syracuse, New York 13210*

The ability of the antioxidant butylated hydroxytoluene (BHT) to combine with free radicals has been described (1). This property, which is the basis of the use of BHT as a food preservative (2, 3), is potentially useful in the study of biological processes involving free radicals. The present experiments were

undertaken to determine a safe dose level for the intraperitoneal injection of BHT.

*Materials and Methods.* Mature female mice were given intraperitoneal injections of BHT dissolved in olive oil in the dose range 0.004–2.5 g/kg. The total volume inoculated was 1 ml (series 1 and 2) or 0.5 ml (series 3 and 4). Control animals were injected with the carrier alone. The mice were killed at periodic intervals and the recovered organs were fixed in 10% buffered formalin and the

<sup>1</sup> This work was supported in part by U.S. Public Health Service Grants, National Institutes of Health and by the Veterans Administration Research Service.

TABLE I. Effect of Intraperitoneal Injection of BHT on Mice.

Series no.	No. of mice	Strain	BHT dose (g/kg)	Vol (ml)	BHT brand	Recovery		Observation
						time (days)	Histology	
1.	5	Ha/ICR, Swiss non-inbred	0	1	σ <sup>a</sup>	—	—	Normal
	5	Ha/ICR, Swiss non-inbred	2.5	1	σ <sup>a</sup>	—	—	Respiratory distress, nonresponsiveness in experimental animals
2.	3	Ha/ICR, Swiss non-inbred	0	1	σ <sup>a</sup>	5	6 major organs	Normal
	12 <sup>o</sup>	Ha/ICR, Swiss non-inbred	0.25, 0.75, 1.25, 2.50	1	σ <sup>a</sup>	5		Lung damage (LD) in all experimental animals, other organs normal
3.	3	DBA/2	0	0.5	σ <sup>a</sup>	3, 5, 7	Lung	Normal
	9 <sup>d</sup>	DBA/2	0.004, 0.04, 0.4	0.5	σ <sup>a</sup>			LD at 3 and 5 days in experimental animals
4.	5	DBA/2	0	0.5	H <sup>b</sup>	3	Lung	Normal
	10	DBA/2	0.28	0.5	H <sup>b</sup>	3		LD in every experimental animal
	10	DBA/2	0.83	0.5	H <sup>b</sup>	3		

<sup>a</sup> Sigma Chemical Co.

<sup>b</sup> Hercules Inc., Daltac R.

<sup>o</sup> Three animals at each dose.

<sup>d</sup> One animal at each dose each day.

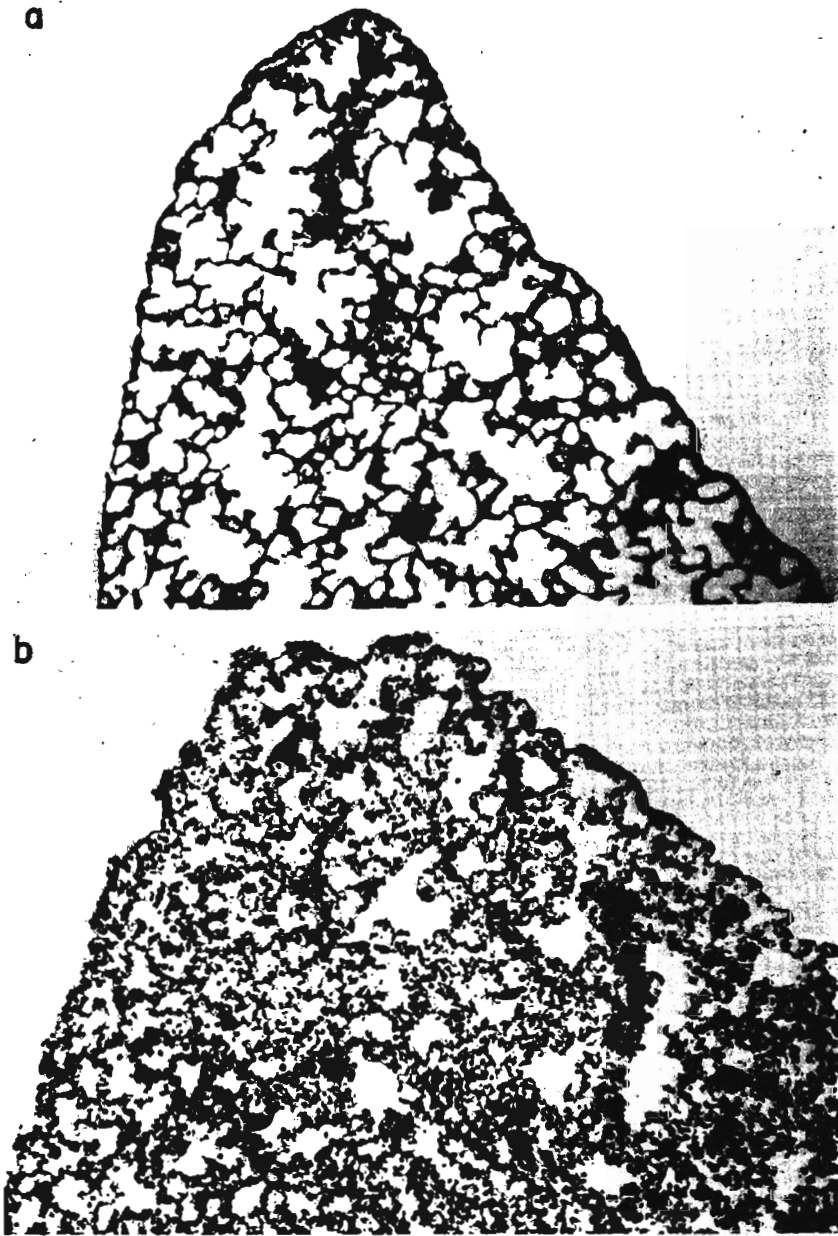


FIG. 1a. Lung of a normal mouse. (b) After intraperitoneal injection of 0.83 g/kg of BHT. ( $\times 100$ ).

sections were stained with hematoxylin and eosin.

*Results.* The results are summarized in Table I. In the first injection series, we observed the gross behavior of five experimental animals (Ha/ICR, Swiss, non-inbred) given a dose of 2.5 g/kg. As early as the first day

postinjection the animals exhibited respiratory distress and were nonresponsive to external stimuli (touch, light, sound); all experimental animals but none of the control animals died within 1 week. In the second series, mice were given doses in the range 0.25–2.5 g/kg. We observed no marked alter-

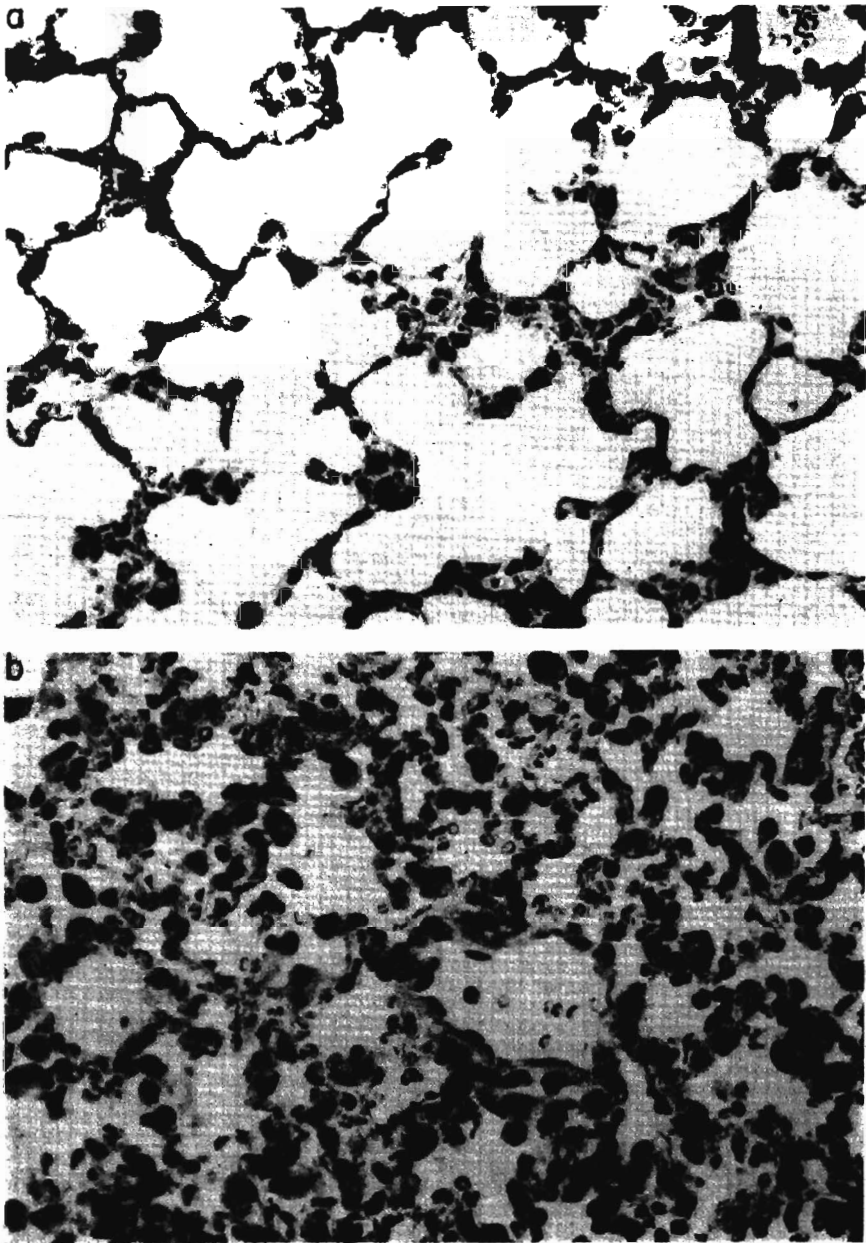


FIG. 2a. Pulmonary alveoli of a normal mouse. (b) After intraperitoneal injection of 0.83 g/kg of BHT. ( $\times 400$ ).

ation in the general appearance and health of the animals who received a dose substantially less than 2.5 g/kg. At 5 days postinjection the animals were killed with an overdose of ether and after gross examination, the liver, kidney, lung, urinary bladder, spleen and ovary were recovered and prepared for light

microscopy. The only gross abnormalities observed were hemorrhagic lungs in the experimental animals. Histologically all organs from the experimental animals were normal regardless of dose, with the exception of the lung.

Control animals exhibited typical normal

lung morphology characterized by branching processes terminating in relatively long, thin-walled alveolar ducts studded with clusters of alveolar sacs and atria (Figs. 1a and 2a). The alveolar sacs consisted of normal inconspicuous alveolar epithelium, a very closely spaced capillary network, and septal cells. In addition, an occasional macrophage was seen in the lumen of some alveolar sacs. The lung tissue from experimental animals was characterized by hyperplasia, hypertrophy and general disorganization of the cellular components (Figs. 1b and 2b). Inter-alveolar septa were thickened with inflammation and displayed increased numbers of pyknotic nuclei and enlarged cells. This proliferation of alveolar cells was accompanied by edema and a marked capillary engorgement and congestion indicating alveolar collapse and disruption. Blebbing of alveolar epithelium and a marked increase of septal cells and macrophages into the alveolar spaces were also routinely seen in all experimental animals. The observed histopathological effects did not vary significantly with dose within the experimental group.

In the third injection series, DBA/2 mice were given doses of either 0.004, 0.04 or 0.4 g/kg, and the lungs were recovered at either 3, 5 or 7 days postinjection. The lungs from the animals given a dose of 0.4 g/kg and recovered at 3 and 5 days exhibited the histopathology described above. The effect on the animals given a dose of 0.04 g/kg was markedly reduced. Only isolated areas of hemorrhage and alveolar wall breakdown were observed. All other animals were normal. The results at this point indicated that the threshold for the histopathological effects was in the vicinity of 0.04 g/kg, and that the effects produced for doses as high as 0.40 g/kg were reversible in the sense that the lungs recovered at 7 days were normal. The last injection series employed a second brand of BHT and was designed to study the frequency and severity of the lung damage produced

at two dose levels. Lung damage as described above was observed in all experimental animals; moderate in 10 animals given a dose of 0.28 g/kg and severe (Figs. 1b and 2b) in 10 animals given a dose of 0.83 g/kg. By comparison the average daily human dietary intake of BHT is about 0.05 mg/kg (4).

Recent studies concerning the toxicology of BHT have dealt primarily with questions of liver enlargement (5-8) and anophthalmia (9-11) in animals fed a BHT-containing diet. With the exception of a brief comment (9), the possibility of lung damage does not appear to have been studied.

*Summary.* Butylated hydroxytoluene was administered intraperitoneally to two strains of mice in the dose range 0.004-2.5 g/kg. Histological examination of the lung tissue revealed thickened interalveolar septa, congestion and a general pattern of tissue disorganization at doses of 0.25 g/kg and above. The observed effects are apparently reversible and have a threshold in the vicinity of 0.04 g/kg.

1. Passwater, R., and Welker, P., *Amer. Lab.* 3, 21 (1971).
2. Deuel, H. J., "The Lipids," Vol. 1, p. 288. Wiley (Interscience), New York (1951).
3. 21 CFR 121.101 (d) (2).
4. *Food Chem. News*, Mar. 9, 3 (1964).
5. Gilbert, D., and Goldberg, L., *Food Cosmet. Toxicol.* 3, 417 (1965).
6. Gaunt, I. F., Feuer, G., Fairweather, F. A., and Gilbert, D., *Food Cosmet. Toxicol.* 3, 433 (1965).
7. Gaunt, I. F., Gilbert, D., and Martin, D., *Food Cosmet. Toxicol.* 3, 445 (1965).
8. Feuer, G., Gaunt, I. F., Goldberg, L., and Fairweather, F. A., *Food Cosmet. Toxicol.* 3, 457 (1965).
9. Frawley, J. P., Kohn, F. E., Kay, J. H., and Calandra, J. C., *Food Cosmet. Toxicol.* 3, 377 (1965).
10. Clegg, D. J., *Food Cosmet. Toxicol.* 3, 387 (1965).
11. Johnson, A. R., *Food Cosmet. Toxicol.* 3, 371 (1965).

Received Dec. 9, 1971. P.S.E.B.M., 1972, Vol. 140.